

RED EYE, RED EYE What do YOU See???

The role of the front office and optometric assistant in the detection and treatment of **RED EYES**

Dr. Kris Kerestan
krisgarbig@fuse.net



Front office staff and assistants are **THE** first ones to begin the **RED EYE** evaluation process when answering the phone...



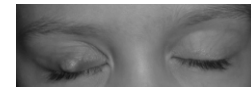
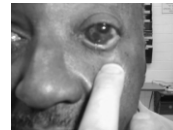FIRST the patient calls the office...

What are some of the most common things they say?

1 Comment:

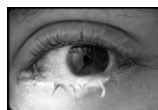"My eye/eyes are **RED**...
I'm afraid I have **PINK** eye"

"I have a **RED** bump on my eye and it's really sore to touch it"



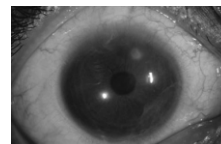
"I woke up with my eye all **RED** and it looks like it's bleeding"

"My eye/eyes are all **RED** and goopy in the morning with yellowish green pus"



"My eyes are so **RED** and itchy... I can hardly stop rubbing them"

"My eyes are **RED** and feel all gritty like I have sand in my eyes"



"I slept in my contact lenses last night and now my eyes are all **RED** and irritated"

“My 2 yr old poked me in my eye last, now it’s all RED and I can hardly keep it opened”



“I purposely poked myself in the eye last night just to impress my friends and now it’s RED and in extreme pain”





“I was doing some work under my car a few days ago and now my eye is all RED and feels like something might be in it”




“I was cutting some drywall last week and it feels like something got in my eye and now it’s all RED”

Next, front office staff and assistants must know the proper questions to ask...

- **WHEN** did the REDNESS begin?
- Are you in any **PAIN**?
- Do you have any **BLURRED VISION**?



- Do your eyes **ITCH, BURN, WATER** or **FEEL IRRITATED**?
- Do you have any **MATTER** in or **SECRETION** from the eye?
- Is the REDNESS in **ONE** or **BOTH** eyes?
- **Light sensitivity**?



What should you do next??


Must determine how quickly the patient needs to be seen...

- **URGENT / IMMEDIATELY!!!**
- **Non-urgent / Later that same day**


URGENT / Immediately!!

REDNESS associated with...

- **Sudden or severe pain and discomfort**
- **Bleeding** in or around the eye



- **Ocular Trauma**
 - Sports injury
 - Auto accident
 - Blow to the eye
 - Fingernail scratch
 - Paper cut
 - Curling iron burn
 - Chemical burn



- **Foreign Body** or object in the eye
- **Extreme** discomfort and sensitivity to light
- **Sudden** change in vision or loss of vision
- **Copious** amount of matter or discharge

Non-urgent / Later the same day


REDNESS associated with...

- **No** ocular trauma
- **No** foreign body injury
- **Mild pain or discomfort** that has been present for several days to a week

- **No** bleeding in or around the eye
- **Little to no** light sensitivity
- **Little to no** change in vision
- **Little to no** matter or discharge

Once the patient comes to the office, then what?

- Case history... Required by medical insurance companies
- All **current** medical insurance information... need payment for services



Specific Case history information is needed...



RED EYE or EYES must be the **CHIEF COMPLAINT**

- Which eye has the problem?
O.D./O.S./O.U.
- Does it cause vision loss or blur?

- Did it occur suddenly or gradually?
- Is the problem mild, moderate or severe?
- How long has it been occurring?
- Are there any associated symptoms?
- Does anything help?

What tests should be performed before the patient sees the doctor?

- Visual Acuity? Always!!!!
- Blood Pressure?
- Intraocular Pressure? Why or why not?
- Any others?

What are some of the most common causes of RED EYE in an Optometric Office...

Any ideas???


- Signs, Symptoms, Treatment**
- Signs – What we clinically observe
 - Symptoms – What the patient is feeling and experiencing
 - Treatment – What we do to manage the condition

- RED EYELID / EYELIDS**
Most Common Conditions
- Hordeolum – Internal and External
 - Chalazion
 - Blepharitis
 - Meibomianitis
 - Trichiasis
 - Eyelid Trauma


**Red EyeLID or EyeLIDS :
Conditions and Treatment**

- **Hordeolum (Stye)**

Localized **infection** or inflammation of the eyelid margin that involve hair follicles of eyelashes (external) or oil glands underneath eyelid (internal)



Red EyeLID or EyeLIDS




Signs:

1. Redness
2. Swelling
3. Bump on the **outside** or **inside** of the lid
4. Ptosis


Red EyeLID or EyeLIDS:

Symptoms:

1. Sore and tender to the touch
2. Mild, Moderate or Extreme Pain




Red EyeLID or EyeLIDS



Treatment:

1. Warm/Hot Moist heat
Bruder Mask
"Hot Potato"
2. Topical Antibiotics, usually an ointment
3. Oral antibiotics, if required

Red EyeLID or EyeLIDS



■ **Chalazion**

Hard eyelid lump caused by a single blocked or series of blocked oil glands...
NOT infectious


Red EyeLID or EyeLIDS

Signs:

1. Redness
2. Swelling
3. Hard lump/bump on inside or outside of the eyelid

Symptoms:

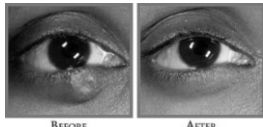
1. No pain or tenderness
2. Cosmesis



Red EyeLID or EyeLIDS

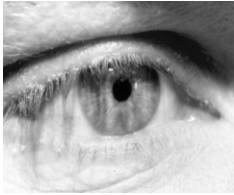
Treatment:

1. Bruder Mask/ "Hot Potato" compress
2. Monitor for change
3. Excise if does not resolve



BEFORE AFTER

Red EyeLID or EyeLIDs



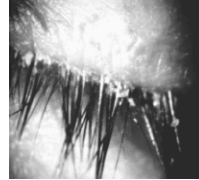
■ Blepharitis

Infection and inflammation of the outer eyelid glands along the entire eyelid margin

Red EyeLID or EyeLIDs

Signs:


1. Redness of eyelids at eyelid margins
2. Crustiness along the base of the lids and lashes
3. Tendency to frequently rub eyes



Red EyeLID or EyeLIDs

Symptoms:


1. Itching of eyelids
2. Grittiness of lids
3. Burning and ocular irritation
4. Watering of the eyes



Red EyeLID or EyeLIDs

Treatment:

1. Hot soaks and lid massage
2. Commercially available eyelid scrubs (w and w/o antibiotic)
3. Topical antibiotics usually an ointment



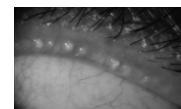
Sight Gags by Scott Lee, O.D.



Red EyeLID or EyeLIDs

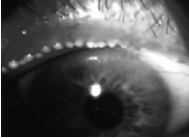
■ Meibomianitis

Infection and inflammation of the inner oil eyelid glands along the entire lid margin



Red EyeLID or EyeLIDs

Signs:

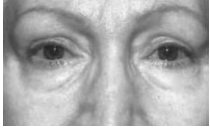


1. Redness and inflammation of inner eyelid margins
2. Toothpaste like excretion from inner eyelid glands

Red EyeLID or EyeLIDs

Symptoms:



1. Burning of the eyes
2. General irritation of the eyes
3. Watering of the eyes



Red EyeLID or EyeLIDs

Treatment:

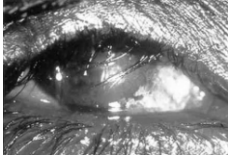
1. Hot moist soaks and massage
2. Bruder Mask
3. MiBo
4. LipoFlow Thermal Pulsation (NEW!)
3. Topical antibiotic
4. Oral antibiotic

Red EyeLID or EyeLIDs

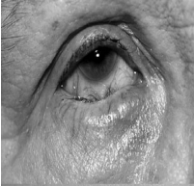
■ Trichiasis

Eyelid lashes that turn inward resulting in scratching of the cornea and conjunctiva



Red EyeLID or EyeLIDs

Signs:



1. Misdirected eyelashes that grow toward eye
2. Redness of the eye

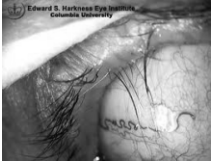
Red EyeLID or EyeLIDs

Symptoms:



1. Scratchy feeling
2. Foreign body sensation
3. Itchiness

Treatment:

1. Removal of lashes
2. Eye drops
3. Bandage Contact Lens if needed



Red EyeLID or EyeLIDs

■ **EyeLid Trauma**

Trauma occurring from sudden impact to the eye and eyelid...car accident, sports injury, blow to the face, chemical burn, etc.

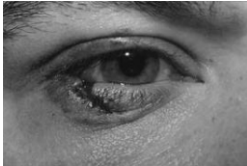
Seriously? WHY??





Red EyeLID or EyeLIDs

Signs:

1. Moderate to severe eyelid redness
2. Possible cut of the eyelid (as seen here)
3. Total lid obliteration (as seen in next slide)



Red EyeLID or EyeLIDs



Symptoms:

1. Moderate to severe pain
2. Light sensitive
3. Blurred vision

Treatment:

1. Cold ice packs
2. Pain management
3. Oculoplastic surgery

Which of the RED Eyelid conditions are True Emergencies ?

- Hordeolum – Internal and External
- Chalazion
- Blepharitis
- Meibomianitis
- Trichiasis
- Eyelid Trauma

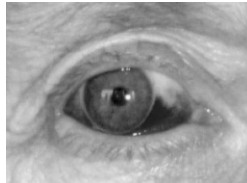
RED Conjunctiva and Sclera Common Conditions and Treatment

- Subconjunctival Hemorrhage
- Pinguecula
- Pterygium
- Seasonal Allergic Conjunctivitis
- Acute Allergic Conjunctivitis
- Bacterial Conjunctivitis
- Contact Lens Associated Red Eye (CLARE)

RED Conjunctiva and Sclera

■ **Subconjunctival Hemorrhage**

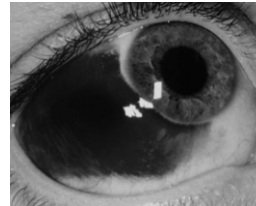
Breaking of the tiny blood vessels between the conjunctiva and the sclera



RED Conjunctiva and Sclera

Signs:

1. Bloody looking eye
2. Well defined area of redness and bleeding
3. Flat or slightly raised hemorrhage



RED Conjunctiva and Sclera

Symptoms...Usually None!

1. No Pain
2. No irritation
3. No discomfort

RED Conjunctiva and Sclera

Treatment:

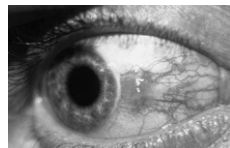
1. Check BP
2. Reassurance
3. Cold compresses followed by hot compresses
4. Artificial tears



RED Conjunctiva and Sclera

■ **Pinguecula**

Localized inflammation of the conjunctiva in the interpalpebral space

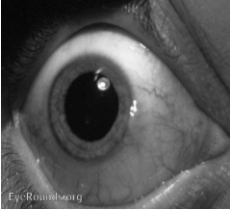


RED Conjunctiva and Sclera

Signs:

1. Reddish yellow inflammation with blood vessels running through
2. Blood vessels and inflammation stops at the limbus

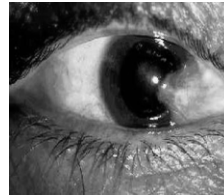RED Conjunctiva and Sclera



- Symptoms:**
1. Usually just bothersome appearance
 2. May cause minor irritation

- Treatment:**
1. Artificial Tears
 2. Topical anti-inflammatory drops
 3. Sunglasses

RED Conjunctiva and Sclera



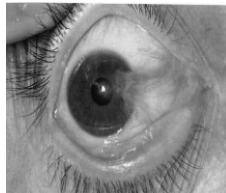■ **Pterygium**

Pronounced inflammation and fibrovascular tissue in the interpalbebral space extending past the limbus and into the cornea

RED Conjunctiva and Sclera

Signs:

1. Appearance of a raised whitish triangle shaped vascular tissue "growing over the eye"



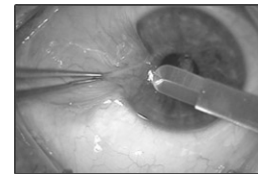
Symptoms:

1. Cosmetic concern over appearance
2. Dry irritated eye

RED Conjunctiva and Sclera

Treatment:

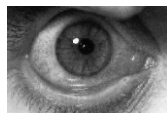1. Monitor closely
2. Use of UV blocking sunglasses
3. Liberal use of Artificial tears
4. Surgical excision when encroaching on the pupil



RED Conjunctiva and Sclera

■ **Seasonal Allergic Conjunctivitis**

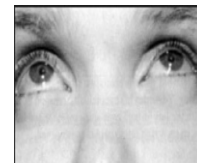Inflammation of the conjunctiva coinciding with pollen blooms, ragweed, animal dander, dust mites...



RED Conjunctiva and Sclera

Signs:

1. Mild diffuse pinkness of the conjunctiva
2. Hazy conjunctiva
3. Rubbing of the eyes... "universal sign"
4. Watery or white stringy discharge
5. Red swollen eyelids



RED Conjunctiva and Sclera



Symptoms:

1. Itching of the eyes which gets worse with rubbing
2. Tearing of the eyes
3. Mucus in corners
4. Sneezing

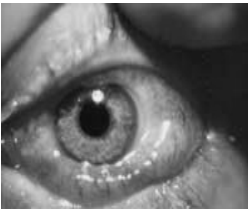RED Conjunctiva and Sclera

Treatment:

1. Avoid offending allergen (pollen blooms, animal dander, dust mites)
2. OTC allergy eye drops
3. Prescription allergy drops
4. Cool compresses
5. Oral allergy meds-Zyrtec, Claritin, Benadryl



RED Conjunctiva and Sclera



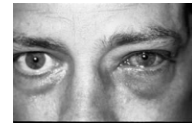■ Acute Allergic Conjunctivitis

Sudden, extreme inflammation caused by an abrupt exposure to a specific allergen

RED Conjunctiva and Sclera

Signs:

1. Extreme redness of the conjunctiva
2. Profound conjunctival chemosis (glassy appearance)
3. Red, swollen and edematous eyelids



RED Conjunctiva and Sclera

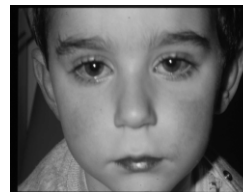
Symptoms:

1. Sudden intense itching and tearing
2. Ocular burning
3. Photophobia

Treatment:

1. Identify and remove offending allergen asap
2. Cold compresses for eyelid swelling
3. OTC oral antihistamine such as Benadryl
4. Prescription allergy and/or anti-inflammatory drops

RED Conjunctiva and Sclera




■ Bacterial Conjunctivitis

Highly contagious infection of the conjunctiva caused by a multitude of bacterial strains

RED Conjunctiva and Sclera

Signs:


1. Reddish "Pink" eye that usually starts in one eye... often moves to the other (Highly contagious)
2. Yellowish discharge



RED Conjunctiva and Sclera

Symptoms:


1. Eyelids feel "glued shut" in the morning
2. Buildup of yellowish green discharge through the day
3. Mild to moderate irritation
4. Patient is usually "sick"



RED Conjunctiva and Sclera

Treatment:

1. Topical antibiotic eye drops or ointment
2. Oral prescription antibiotics
3. Hot compresses




RED Conjunctiva and Sclera

■ **Contact Lens Associated Red Eye (CLARE)**

Signs:


Redness around the limbus usually due to over wear of CLs or solution intolerance



RED Conjunctiva and Sclera

Symptoms:


1. Mild to moderate pain especially when wearing CLs
2. Tearing
3. Photophobia



RED Conjunctiva and Sclera

Treatment:

1. Discontinuing CL wear (Usually temporarily)
2. OTC or Rx. Eye drops
3. Refit to other type of CL
4. Change CL solution

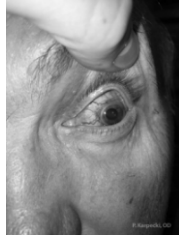

Carotid Cavernous Fistula

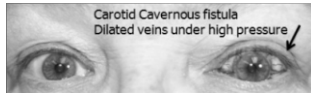
Sudden vascular engorgement and ocular redness secondary to poor circulation of blood in cavernous sinus

Signs:

1. Diffuse injection
2. Engorged "corkscrew" vessels
3. Unilateral



4. Progressive pulsatile proptosis which may cause a humming sound in skull
5. Decrease in VA
6. Increase in IOP due to increased venous pressure
7. Intolerable pain
8. Young adults – Head trauma
9. Older adults – Progressive atherosclerosis
10. May lead to neurological deficits or a fatal brain hemorrhage



Treatment:

1. Order CT scan and MRI to look for an enlarged superior ophthalmic vein
2. Refer to Neurologist/ Vascular surgeon

Which of the RED Eye conditions of the Conjunctiva are True Emergencies?

- Subconjunctival Hemorrhage
- Pinguecula
- Pterygium
- Seasonal Allergy
- Acute Allergy
- Bacterial Conjunctivitis
- CLARE
- Carotid Cavemous Fistula

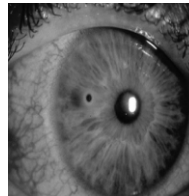
RED EYE associated with Corneal Conditions and Treatment

- Foreign Body
- Abrasion
- Recurrent Erosion
- Dry Eye
- Corneal Infiltrate
- Chemical or UV Damage
- Corneal Trauma

RED EYE associated with Corneal Problem

Corneal Foreign Body

Signs:

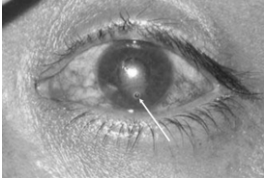


1. Foreign object in eye usually metal, wood drywall, etc.
2. Unable to open eye
3. Light sensitive

RED EYE associated with Corneal Problem

Symptoms:


1. Moderate to extreme pain
2. Feels like something is in the eye
3. Discomfort
4. Photophobia



RED EYE associated with Corneal Problem

Treatment:

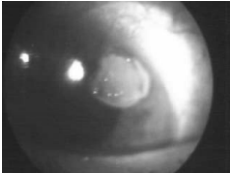
1. Removal of foreign body
2. Topical antibiotics
3. Bandage CL using a continuous wear CL



RED EYE associated with Corneal Problem

■ **Corneal Abrasion**

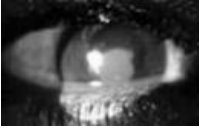
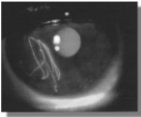
Loss of surface cells on the front surface of the cornea



RED EYE associated with Corneal Problem

Signs:

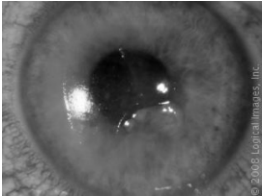
1. Unable to open eye
2. Extremely light sensitive
3. Appearance of scratch or section of cornea removed

RED EYE associated with Corneal Problem

Symptoms:

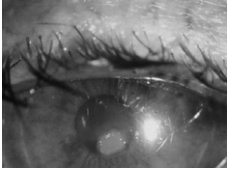
1. Moderate to extreme pain
2. Feels like something is in the eye



RED EYE associated with Corneal Problem

Treatment:

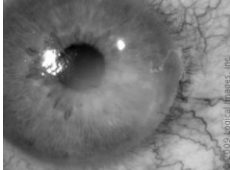
1. Topical antibiotic eye drops
2. Fitting of a bandage CL until resolves
3. Prophylactic nightly use of lubricating eye ointments



RED EYE associated with Corneal Problem

■ **Recurrent Corneal Erosion**

Sporadic and spontaneous removal of the front surface cells of the cornea after previous corneal abrasion



RED EYE associated with Corneal Problem

Signs:

1. Redness upon awakening
2. Watery and tearing of the eye

Symptoms:

1. Pain and irritation upon awakening
2. Feels like something is in the eye
3. Light sensitive

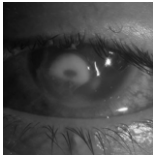
Treatment:
Prophylactic use of lubricating eye gels or ointments at bedtime to minimize future erosions

RED EYE associated with Corneal Problem

■ **Contact Lens Associated Keratitis**

Corneal inflammation resulting from various CL related issues that can eventually result in fungal keratitis

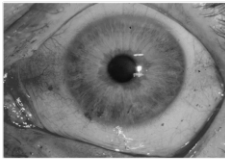
- Overwear
- Poor hygiene
- Solution (ReNu Moisture-Loc)



RED EYE associated with Corneal Problem

■ **Dry Eye Syndrome**

Chronic lack of lubrication and moisture of the eye due to many factors including low tear production, poor tear quality and other eyelid issues

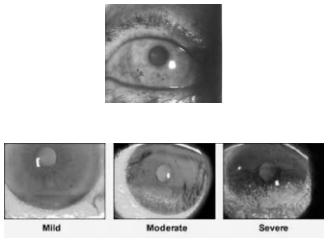


Dry eye, as a disease or a passive condition, may affect an estimated 11% to 22% of the general population. The condition causes burning, stinging eyes.

RED EYE associated with Corneal Problem

Signs:


1. Mild to severe interpalpebral redness
2. Mild to severe corneal staining



RED EYE associated with Corneal Problem

Symptoms:


1. Burning & stinging
2. Grittiness & Scratchiness
3. Foreign Body sensation
4. Photophobia
5. Intermittent blurred vision
6. Watery and tearing



RED EYE associated with Corneal Problem


Treatment:

1. OTC lubricants
 - Refresh Optive/Advanced
 - Systane Ultra/Balance
 - Soothe XP
2. Rx. eye drops
 - Restasis
 - Xiidra
3. Rx. anti-inflammatory eye drops (Steroid)



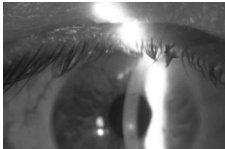
RED EYE associated with Corneal Problem

1. Omega -3
Salmon, Tuna, mackerel, herring, trout, sardines or halibut
2. Ocular Supplements
1000-2000 mg/Day



RED EYE associated with Corneal Problem

■ **Corneal Infiltrate**
Small hazy grey areas of inflammation usually near the limbus



Signs:

1. Redness
2. Tearing

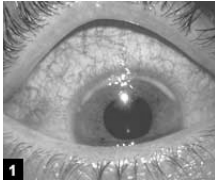
RED EYE associated with Corneal Problem

Symptoms:

1. Foreign body sensation
2. Mild to severe irritation
3. Light sensitive

Treatment:


1. Topical antibiotic-steroid drops



RED EYE associated with Corneal Problem

■ **Chemical Solution/UV Damage**

Damage of the cornea caused by chemical solution or UV exposure



Signs:

1. Redness
2. Chemosis of Conjunctiva
3. Corneal Staining

RED EYE associated with Corneal Problem


■ **Chemical Solution / UV Damage**

Symptoms:

1. Pain and discomfort
2. Tearing, burning and stinging
3. Foreign body sensation

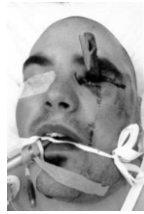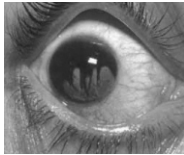
Treatment:

1. Artificial tears
2. Antibiotic / steroid drops
3. Change of CL solution
4. Advise against tanning bed use
5. Sun protection when outside



RED EYE associated with Corneal Problem

■ **Corneal Trauma**



Which of the RED EYE conditions of the Cornea are True Emergencies??

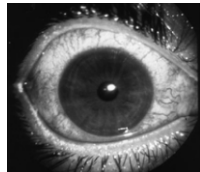
- Foreign Body
- Abrasion
- Recurrent Erosion
- Dry Eye
- Corneal Infiltrate
- Chemical or UV damage
- Cornea Trauma

RED EYE associated with Uveal Tract

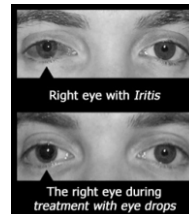
■ **Anterior Uveitis**
Inflammation of the middle layer of the eye

Signs/Symptoms:

1. Red, sore, inflamed eye
2. Blurred vision
3. Light sensitivity
4. Small pupil



RED EYE associated with Uveal Tract

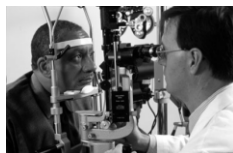


Treatment:

1. Cycloplegia
2. Topical steroids

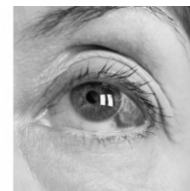
Once the doctor examines the Red Eye Patient...how do YOU come back in the picture?

- Exam room assistance
- Patient education
- Follow-up care



Can you identify THIS Red EYE ?


- Woke up with it
- No pain
- No discomfort
- No blurred vision



Is that your Final Answer?

- A. Allergic Conjunctivitis
- B. Pinguecula
- C. Subconjunctival Hemorrhage
- D. Pterygium

Can you identify THIS Red EYE ?



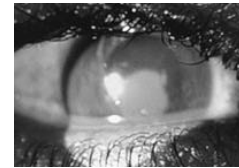
- Itchiness
- Scratchiness
- Burning
- Irritation
- Frequently rubs eyes

Is that your Final Answer?

- A. Hordeolum
- B. Blepharitis
- C. Foreign Body
- D. Meibomianitis

Can you identify THIS Red EYE ?

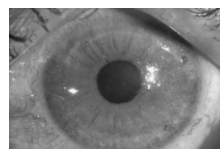
- Toddlers finger scratched eye
- Pain
- Tearing
- Hard to open
- Blurred Vision



Is that your Final Answer?

- A. Dry Eye
- B. Recurrent Corneal Erosion
- C. Corneal Abrasion
- D. Corneal Foreign Body

Can you identify THIS Red EYE ?



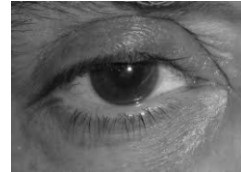
- Burning
- Itching
- Watering
- Grittiness
- Irritation
- Eye strain
- Eye Fatigue

Is that your Final Answer?

- A. Digital Eye Strain
- B. CLARE
- C. Dry Eye
- D. Seasonal Allergy

Can you identify THIS Red EYE ?

- Red Bump on Lid
- Moderate Soreness
- Tender to the touch

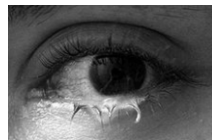

Is that your Final Answer?

- A. Chalazion
- B. Entropion
- C. Hordeolum
- D. Trichiasis

Can you identify THIS Red EYE ?

- Woke up with eyes "glued" shut
- Yellowish matter through the day
- Mild irritation
- Had a cold last week

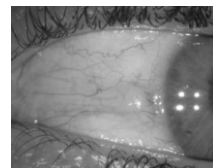


Is that your Final Answer?

- A. Acute Allergic Conjunctivitis
- B. Seasonal Allergic Conjunctivitis
- C. Dry Eye
- D. Bacterial Conjunctivitis

Can you identify THIS Red EYE ?

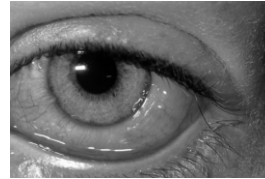
- Yellow raised bump on white part of the eye
- Worse after being outside in sun and wind
- Mild occasional irritation



Is that your Final Answer?

- A. Subconjunctival Hemorrhage
- B. Pinguecula
- C. Pterygium
- D. Bacterial Conjunctivitis

Can you identify THIS Red EYE ?




- Itching
- Always rubbing eyes
- Watering
- Sneezing
- Allergies

Is that your Final Answer?

- A. CLARE
- B. Acute Allergic Conjunctivitis
- C. Seasonal Allergic Conjunctivitis
- D. Subconjunctival Hemorrhage

RED EYE??

THANK YOU!



Dr. Kris Kerestan krisgarbig@fuse.net